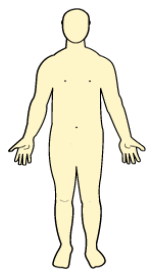





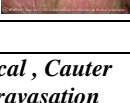








Patient Number کد بیمار:	Chart Number شماره پرونده:	وزارت بهداشت و درمان و آموزش پزشکی معاونت پرستاری برگه مدیریت زخم	Name نام:	Family Name نام خانوادگی:
Admission Date تاریخ بستری:	Diagnosis تشخیص:		Bed تخت:	Ward بخش:





<p>Back</p> 	<p>Front</p> 	<p>Right</p> 	<p>Left</p> 
mark location of wounds with number			

Type of Wound	1	2	3	4
Pressure ulcer				
first degree 				
second degree 				
third degree 				
forth degree 				
deep tissue injury 				
Unstageable 				
Other Wounds				
<i>Diabetic , Surgical , Cauter Vascular , Extravasation</i>				

Wound Bed				
Necrotic(hard) 				
Necrotic(soft) 				
Sloughy 				
Granulating 				
Epithelialising 				
Haematoma 				

Wound Dimensions (mm)	1	2	3	4
Length / Width / Depth				
Undermining (location-size)				
Sinus (location-size)				

Wound Exudate				
Level / Type				
low/moderate/high				
serous/haemoserous/purulent				

Peri-wound Skin				
intact				
Excoriated				
Edematous				
macerated				

Signs of Infection				
heat				
new slough/necrosis				
increasing pain				
increasing exudate				
increasing odour				
friable granulation tissue				

Management				
cleansing,debridement,dressing				

© Copyright Bahram Ghaderi, 2016

تاریخ

ساعت

درمانگر زخم